CE: Pediatric Intoeing • Puncture Wounds • Hammertoe Surgery • Pediatric Flatfoot

Podiatry Today

www.podiatrytoday.com January 2007

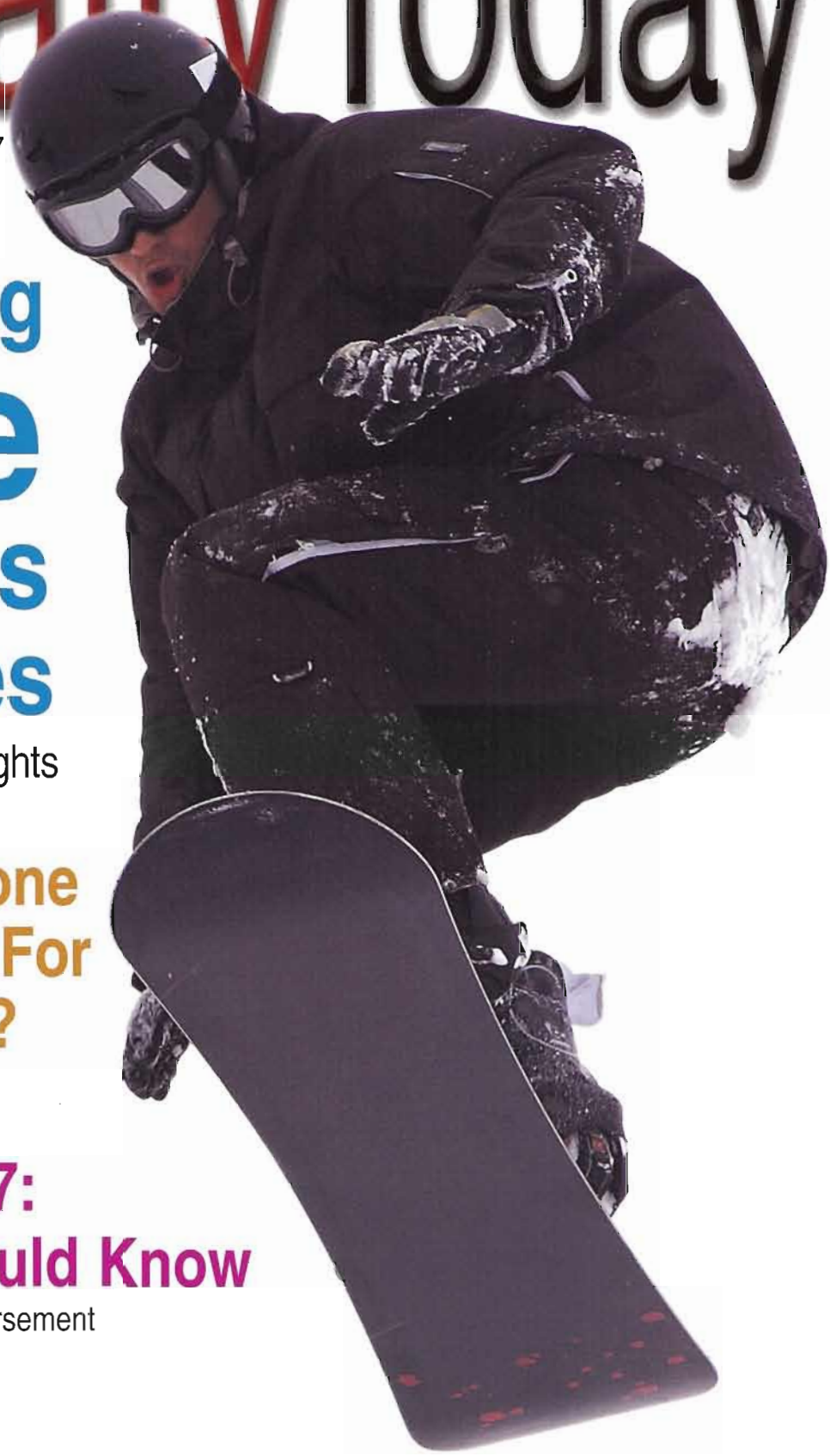

Conquering Ankle Fractures In Athletes

Essential treatment insights

Is Probe To Bone The Best Test For Osteomyelitis?

Two DPMs debate the issue

Coding In 2007: What You Should Know

How to ensure optimal reimbursement

HMP Communications

Clinical Editor: Jesse Burks, DPM

Is The InterPhlex A Viable Option In Hammertoe Surgery?

By Kerry Zang, DPM

One of the most common conditions that the foot and ankle surgeon will encounter is the hammertoe deformity. Surgeons have used multiple procedures for more than 60 years to deal with this condition. These have included amputation of the digit, arthrodesis of the interphalangeal joints, soft tissue releases, arthroplasty (removal of bone, partial or complete), tendon transfers, implants and/or a combination of the above. The most popular procedure during this time has been the arthroplasty with resection of the head of the proximal phalanx.

However, a new interphalangeal digital implant has emerged for the correction of hammertoe deformities. Podiatric surgeons may utilize the InterPhlex (OsteoMed) to augment arthroplasty procedures with the implant functioning as an interphalangeal stabilizing rod and joint spacer.

As podiatric surgeons, we now know that a combination of etiologic factors contributes to the formation of the hammertoe deformity. These factors include but are not limited to the following: mechanical imbalances between the long flexor and extensor muscles and tendons; weakness of the intrinsic muscles of the foot; injury; systemic collagen and neuromuscular disorders; and degenerative capsulopathy (plantar plate derangement) of the metatarsophalangeal joint.

In preparation for the reconstructive surgical procedure, one must consider and address all of the aforementioned factors in order to achieve optimal results.

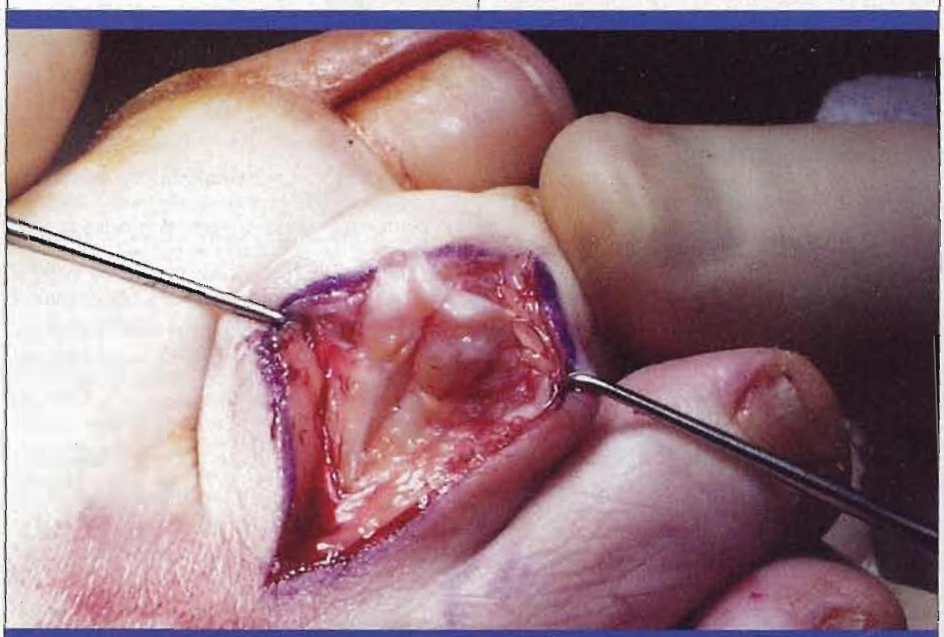

After making and deepening an incision, visualize the extensor tendon and incise it from proximal to distal, thus exposing the head of the proximal phalanx as one can see here.

How The InterPhlex Implant Works

The foot and ankle surgeon can use the InterPhlex interdigital implant to stabilize the digit and help maintain the length of the toe after an arthroplasty, a joint resection procedure. The implant is 28 mm in length and has a stem diameter of 2.2 mm. At the two-thirds mark in the implant, there is a circular ball that helps maintain the length of the digit by preventing the rod portion from migrating. This circular ball also functions as a fulcrum to help maintain some motion. Two sizes (4 mm and 4.5 mm) are available for the circular portion of the spacer.

This implant is not a joint replacement device but is rather a functional spacer and stabilizing rod. As the operative site heals, there is increased stability due to the development of dense fibrous tissue around the implant in the area of the joint resection. This dense fibrous tissue then develops into a flexible fusion.

A Guide To The Surgical Procedure

To initiate the surgical procedure, the surgeon should make a slightly serpentine incision from the base of the proximal phalanx to the distal interphalangeal joint. Deepen the incision, visualize the extensor tendon and incise it from proximal to distal, thus exposing the head of the proximal phalanx.

The surgeon should accomplish an osteotomy or arthroplasty using a micro sagittal saw, excising the head of the proximal phalanx at the level of the anatomical neck. One should resect approximately 6 to 8 mm of bone.

Proceed to use a 2.2-mm drill to

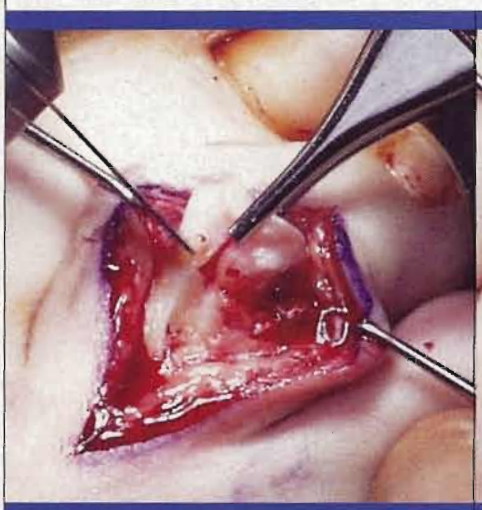

Using a micro sagittal saw, excise the head of the proximal phalanx at the level of the anatomical neck. Resect approximately 6 mm to 8 mm of bone.

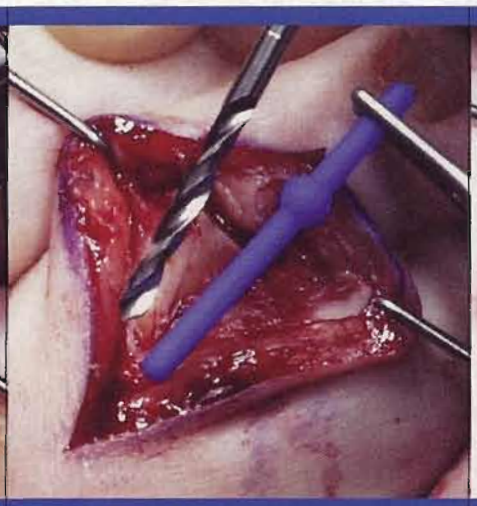

Use a 2.2-mm drill to ream out the proximal and middle phalanges. Place the longer stem of the implant into the proximal phalanx and the shorter stem into the middle phalanx.

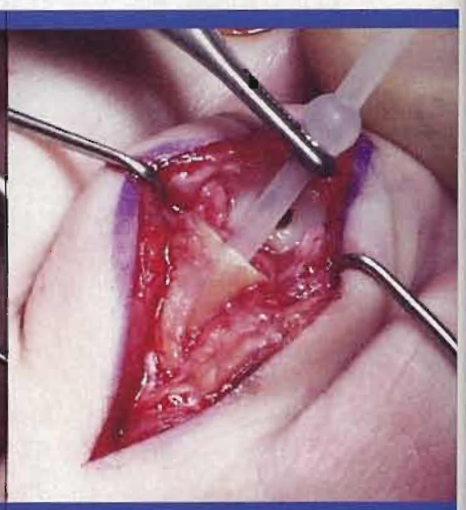

As seen here, remove the sizer and irrigate the operative site with copious amounts of antibiotic irrigation to remove osseous debris that might be present.

ream out the proximal and middle phalanges. The drill has special markings so the drill hole corresponds precisely to the diameter of the rod portions of the InterPhlex implant. One would place the longer stem of the implant into the proximal phalanx and place the shorter stem into the middle phalanx.

One would determine the appropriate size for the implant by placing the sizer in position within the digit. Check the alignment. Remove the sizer and irrigate the operative site with copious amounts of antibiotic irrigation to remove any osseous debris that might be present. Then place the actual implant in position in the digit. One should then repair the extensor tendon and close the skin edges in the standard manner.

Podiatric surgeons should obtain intraoperative X-rays or fluoroscopic views prior to applying the final dressings. Doing so helps ensure that the implant is well seated in both the proximal and middle phalanges, and the toe is in good alignment.

Postoperative care depends on the preference of the podiatric surgeon. Splinting the toe for several weeks is helpful. One should remove sutures in approximately 14 days and the patient can return to shoes in three to six weeks as tolerated.

What Are The Key Advantages Of The Implant?

There are many potential benefits by using the InterPhlex interdigital implant. The device reestablishes the alignment of the digit as the rod portion of the implant places the intermediate and distal phalanges in line with the proximal phalanx. The device also maintains toe stability. The InterPhlex also maintains some flexibility as the fibrous sheath that forms is dense but not rigid. There is usually less postoperative edema when compared to a straight arthroplasty procedure as the circular spacer portion of the implant presses against the remaining portion of the osteotomized proximal phalanx. This helps to reduce intracapsular hematoma formation.

Another advantage is that the implant also functions as a tissue expander. If the unlikely situation arises whereby the surgeon needs to remove the implant, the fibrous tissue is dense enough to maintain flexibility, stability and length. This helps to prevent the occurrence of a flail and floppy digit.

Also significant is the fact that by reducing the tension on both the extensors and flexors by approximately 2 mm to 3 mm, the implant functionally lengthens the supporting soft tissue structures. This often negates the need for tendon lengthening procedures. This is important in maintaining and restoring function.

The use of this device is contraindicated in patients with advanced peripheral vascular disease, open and non-healing wounds, infection, in medically compromised patients and in those patients with unrealistic expectations.

Final Notes

Repair of hammertoe deformities via arthroplasty of the head of the proximal phalanx with the use of a flexible stabilizing rod and joint spacer offers the surgeon an excellent alternative to straight arthroplasty or arthrodesis. ■

Dr. Zang is a Diplomate of the American Board of Podiatric Surgery, and a Fellow of the American College of Foot and Ankle Surgeons. He practices in Mesa, Ariz.

Dr. Burks is a Fellow of the American College of Foot and Ankle Surgeons and is board certified in foot and ankle surgery. Dr. Burks practices in Little Rock, Ark.

Editor's note: For related articles, see "Point-Counterpoint: Is Fusion The Best Option For Crossover Toe Deformity?" in the October 2005 issue.